Slide 1

RADIATION TREATMENT OPTIONS

Sharon Jamison, BSN, RN, CORLN

Slide 2

DISCLOSURES

- The presenter has no disclosures nor does she have any financial interest in any discussed topics.

Slide 3

GOALS

- Explanation of radiation- spectrum, actions and indications
- Discussion of the types of radiation therapies
- Enumeration of radiation effects on integumentary, endocrine, vascular, pulmonary, digestive systems

Slide 4

ENERGY SPECTRUM



Slide 5

TYPES OF RADIATION

Non-Ionizing
- Thermal
- Radio waves
- Microwaves
- Infrared
- Visible light
- Ultraviolet

Ionizing
- X rays
- Gamma
- Particle radiation
  - Alpha
  - Beta
  - Neutron

Slide 6

IONS

- What are ions?
  - **Atoms with an electrical charge**
    - Protons/ electrons
      - Anions-Negative charge
      - Cations- Positive charge
- Ionization
  - **Electrically neutral atom**
    - Loss of an electron to produce a positively charge atom
    - Loss of a proton to produce a negatively charged atom

Slide 7

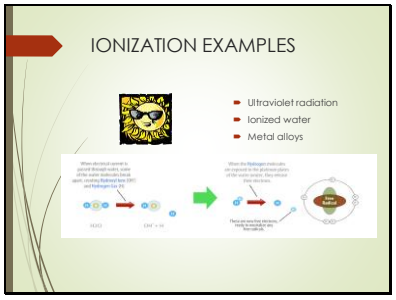

Slide 8

Slide 9

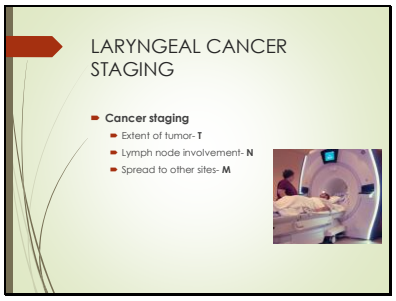

Slide 10

LARYNGEAL CANCER STAGING

AJCC Stage	Stage Group	Stage Description
0	Tis N0 M0	Tumor is in top layer/ lining of larynx. No lymph node involvement, no distant metastasis
I	T1 N0 M0	Tumor has grown deeper into vocal cord, but, has not affected movement. No lymph node involvement, no spread past VC.
II	T2 N0 M0	Tumor spread to supraglottis or subglottis. No lymph node involvement or spread to distant parts of the body
III	T3 N0 M0	Tumor still contained in larynx, but, vocal cord movement is affected **or** tumor has spread to the paraglottic space **or** tumor growth into inner portion of thyroid cartilage. No LN or distant spread.
III	T1 to T3 N1 M0	Tumor still within larynx with/or without VC function affect (tumor is less than 3 cm)/ Spread to a single lymph node of the same side of neck as the tumor/ no distant spread.

Slide 11

LARYNGEAL CANCER STAGING

AJCC Stage	Stage Group	Stage Description
IVA	T4a N0 or N1 M0 — T1-T4a N2 M0	Tumor grown through thyroid cartilage and/ or grown into tissues past larynx. No LN spread or one involved LN on same side (ipsilateral), no larger than 3 cm. No distant spread. Moderately advanced local disease ——————— Tumor may or may not have grown into structures outside larynx and it may or may not affect VC function, but: • Cancer has spread to a single ipsilateral LN, larger than 3 cm, OR • Spread to more than one ipsilateral LN, none larger than 6 cm OR • Has spread to at least one LN the other side (contralateral) of the neck- none larger than 6 cm across No cancer spread to distant sites.
IVB	T4b Any N M0 — Any T N3 M0	Tumor growth into areas in front of spine (prevertebral space), surrounds a carotid artery, or is growing down into space between lungs Very advanced local disease. Positive or negative LN involvement No cancer spread to distant sites. ——————— Tumor growth may or may not have invaded structures outside of larynx and may or may not affect VC function, but: Cancer spread to at least one lymph node larger than 6 cm, OR has spread to LN has grown outside of LN (ENS). No spread to distant sites.
IVC	Any T Any N M1	+ LN growth into structures outside larynx, + or -VC affect, + or -LN spread, but, + spread to distant parts of the body.

Slide 12

LARYNGEAL CANCER TREATMENT

- Non-surgical treatments
  - Radiation
  - Chemotherapy
  - Combined modality
  - Surgery
  - Salvage surgery

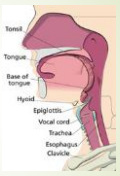

Slide 13

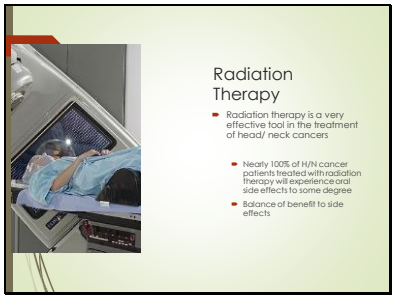

Slide 14

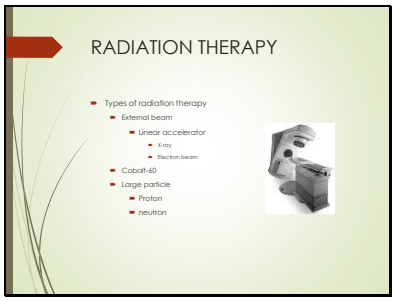

Slide 15

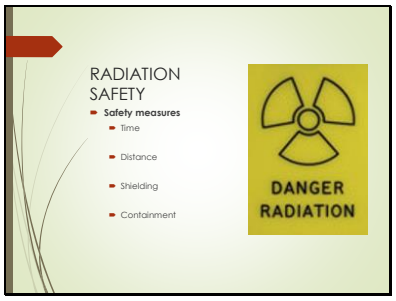

Slide 16

Slide 17

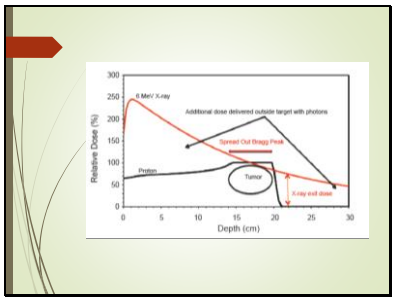

Slide 18

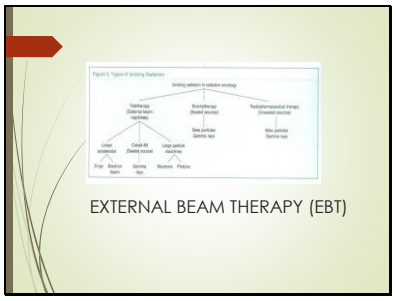

Slide 19

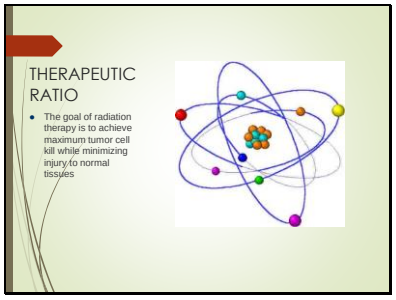

Slide 20

Slide 21

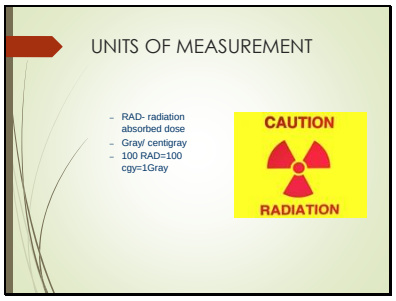

Slide 22

COMBINED MODALITY THERAPY

- Enhanced tumor cell kill
- Chemotherapeutic agents- daxorubicin, actinomycin-D, cyclophosphamide, bleomycin, cisplatin, taxotere
- Radioprotectors- protect oxygenated (normal) cells during radiation therapy
- Phase II and III clinical trials continue to search for efficacy

Slide 23

COMBINED MODALITY THERAPY

- Neoadjuvant therapy- chemotherapy before local radiation: shrinks tumor burden
- Concomitant therapy- chemotherapy is given with radiation (increased/ enhanced tumor cell kill)
- Adjuvant therapy- chemotherapy given after a course of radiation

Slide 24

SIMULATION

- Simulation-provides information to determine the exact dose required for the target volume
- Identification of treatment field
- Area marked with tattoos/ markings to replicate the target treatment field daily

Slide 25

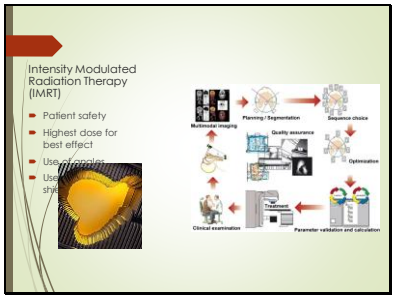

Slide 26

Slide 27

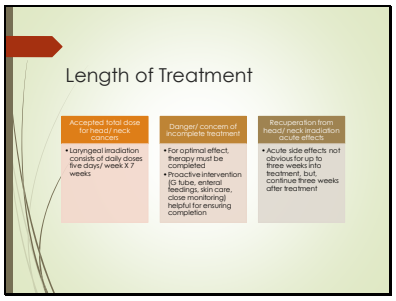

Slide 28

ACUTE EFFECTS

- Acute effect of radiation therapy occur mainly in normal cells that regenerate rapidly
  - Acute toxicities vary with the patient, area being treated, duration of treatment
    - Resolution of acute reactions depends on tissue being treated and degree of reaction to the radiation

Slide 29

SKIN EFFECTS

- Effects of radiation on skin
  - Most patients experience some degree of skin dryness, itching, erythema
  - Degree of skin reaction dependent on amount of treatment as well as anatomic location of the treatment field, proximity of the tumor to the skin surface, nutritional status of the patient, other treatment modalities at the time of radiation treatment, comorbidities

Slide 30

Skin effects

- Erythema- transient- within hours to days
- Erythema proper- following 2-3 weeks of start of treatment; resolves 20-30 days after last treatment
- Pruritis- itching occurs as epidermis thins and sebaceous and sweat gland production decreases
- Hyperpigmentation- tanned appearance of skin; melanin is transported to superficial skin layers
- Dry desquamation- occurs 3-4 weeks after radiation initiation; resolves 1-2 weeks after completion

Slide 31

Skin effects

- Subacute effect phase
  - Damage is seen in weeks to a few months after completion of radiation
  - Moist desquamation- occurs after delivery of 40 Gy or with trauma of skin or excessive friction; skin sloughs, bright erythema, serous exudate, pain. Epithelium has been destroyed
  - Skin regrowth after moist desquamation- Usually complete after 2-3 months after completion of treatment

Slide 32

SKIN EFFECTS

Dry/ moist desquamation

Resolution of desquamation

Slide 33

LATE SKIN EFFECTS

- Photosensitivity- lifelong. Due to destruction of melanocytes and slower melanin response to UV rays
- Pigmentation changes- hypo or hyperpigmentation- disruption of melanocytes
- Atrophy- permanent. Thin and fragile epidermis
- Fibrosis- usually begins 4-6 months after completion of treatment. May worsen over time
- Telangiectasia- may occur up to 8 years after treatment

Slide 34

Slide 35

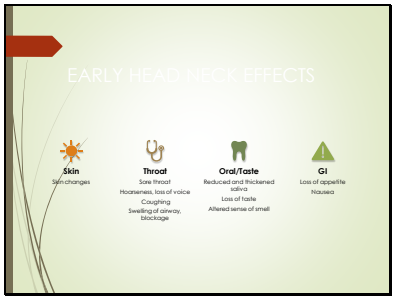

Slide 36

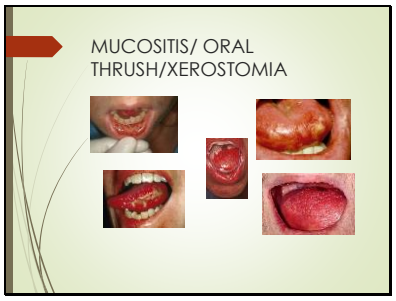

Slide 37

HEAD NECK LATE EFFECTS

- Dry mouth (xerostomia)
- Altered sense or loss of taste
- Tooth decay, gum changes
- Bone (jaw) damage, stiffness or limitation of jaw movement,
- Swelling of tissues under chin (lymphedema)
- Throat damage (difficulty swallowing, breathing, hoarseness, pain)
- Thyroid gland damage (may require long term hormone replacement)

Slide 38

LYMPHEDEMA

- Lymphedema presentation
  - Heaviness, tightness of skin
  - Difficulty swallowing
    - No obvious reason for complaints
    - Lack of treatment leads to facial, neck swelling, impaired range of motion, fibrosis
    - Dysphagia due to internal lymphedema
    - May impact breathing
    - Definite negative impact to quality of life

Slide 39

INTERNAL LYMPHEDEMA

Slide 40

CONCLUSION

- External beam radiation therapy
  - Treatment of choice for T1 and T2 laryngeal cancers
  - May be combined with chemotherapy, radiosensitizers, targeted therapies
  - May be used for more advanced cancers, assist in debulking
  - Side effects of XRT may intensify, become more troublesome later on
  - Exciting advances in XRT options may reduce side effects, increase treatment success

Slide 41

Questions?

Slide 42

REFERENCES

- American Cancer Society. (12/2017). Laryngeal cancer stages. Retrieved December 28, 2018 from: www.cancer.org
- Furlow B. (Feb 2018). Cost vs. benefits: The controversy over proton beam radiotherapy. Oncology Nurse Advisor. Retrieved January 4, 2018 from:
- https://www.oncologynurseadvisor.com/general-oncology/cost-vs-benefits-the-controversy-over-proton-beam-radiotherapy/article/747118/
- Gantley, J.; Pahel, S.; Mahyar, J.; et al. (January 2006). Results of surgical salvage after failure of definitive radiation therapy for early-stage squamous cell carcinoma of the glottic larynx. Archives of Otolaryngology Head Neck Surgery, 132(1): 59-66. doi:10.1001/archoto.132.59
- Liu, A., Swisher-McClure, S., Millar, L., Kirk, M., Yeager, C., Boong-Keng, A., Teo, K., Hahn, S. (Dec. 2012). Proton therapy for head and neck cancer: Current applications and future directions. Department of Radiation Oncology, University of Pennsylvania, Philadelphia. Translational Cancer Research, Dec. 2012 (1): 4. doi:10.3978/j.issn.2218-676X.2012.12.01
- Sandulache, V.; Vandelaar, L.; Skinner, H.; Caton, J.; Hutcheson, K.; Fuller, C.; Phan, J.; Siddiqui, F.; Lai, S.; Weber, R.; Zafereo, M. (April 2016). Salvage total laryngectomy following postoperative proton radiation therapy: A 20 year experience. Head Neck, Apr; 38(Suppl 1): E1962-E1968. doi:10.1002/hed.24355
- Tian, X.; Liu, K.; Hou, Y.; Cheng, J.; Zhang, J. (Nov. 2017). The evolution of proton beam therapy: Current and future status. Molecular and Clinical Oncology. 2018, Jan. (1):15-21. doi: 10.3892/mco.2017.1499